

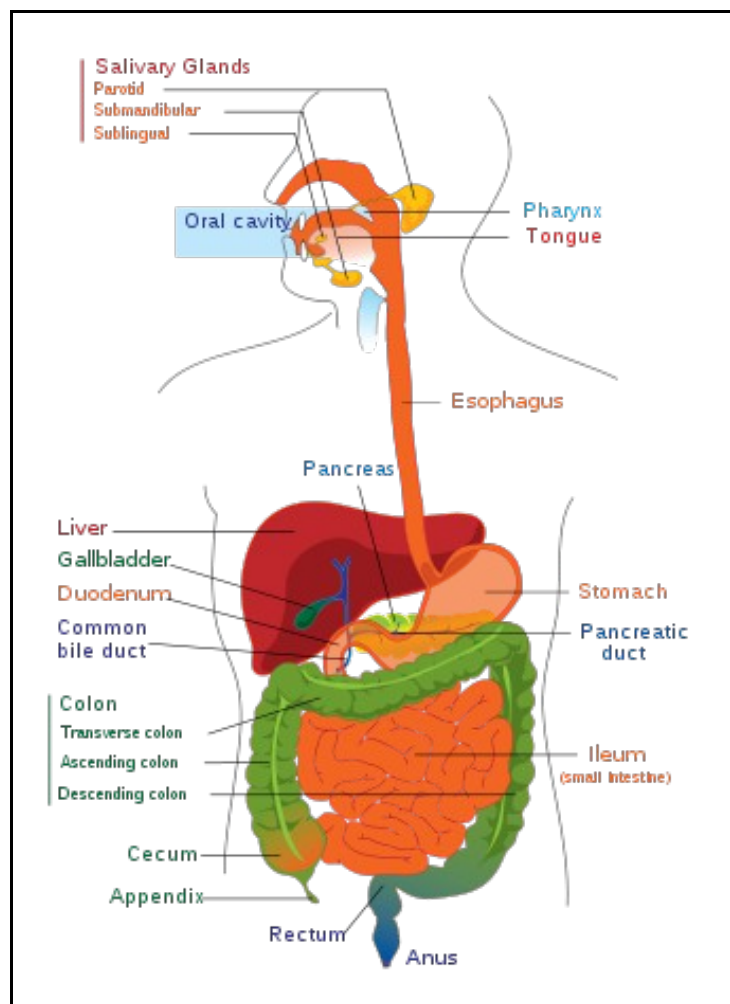
Gastrointestinal Endoscopy -Landscape Report

Contents

- 1 Overview
 - ◆ 1.1 Introduction
 - ◆ 1.2 Procedures
- 2 GI Imaging
- 3 Product Portfolio Heat Map
- 4 Market Size
 - ◆ 4.1 Major Players
 - ◇ 4.1.1 Detailed Company Profile
 - ◇ 4.1.2 Snapshot Profiles
- 5 M&A Activity
- 6 Procedure Volumes
 - ◆ 6.1 Colon/Rectum cancer
 - ◇ 6.1.1 Volumes, Prevalence and Incidence
 - ◇ 6.1.2 Survival Rates
 - ◇ 6.1.3 Incidence rates
 - ◆ 6.2 Obesity (Gastric bypass/Gastric banding)
 - ◇ 6.2.1 Volumes, Prevalence and Incidence
 - ◆ 6.3 Digestive system disorders
 - ◇ 6.3.1 Volumes, Prevalence and Incidence
- 7 Reimbursements
 - ◆ 7.1 Upper GI/ Colonoscopy
 - ◆ 7.2 Bariatric Surgery
- 8 Technology Advancements

Overview

Introduction



Gastrointestinal Tract

Gastrointestinal Endoscopy deals with the endoscopic examination, therapy or surgery of the gastrointestinal tract. Gastrointestinal Tract generally refers to the digestive structures stretching from the mouth to anus, but does not include the accessory glandular organs such as liver, biliary tract, pancreas. The gastrointestinal tract is categorized into various sections, these include:

- **Intestines:** The section of the alimentary canal from the stomach to the anal canal, includes the large intestine and small intestine.
- **Lower Gastrointestinal Tract:** The segment of gastrointestinal tract that includes the small intestine below the duodenum, and the large intestine.

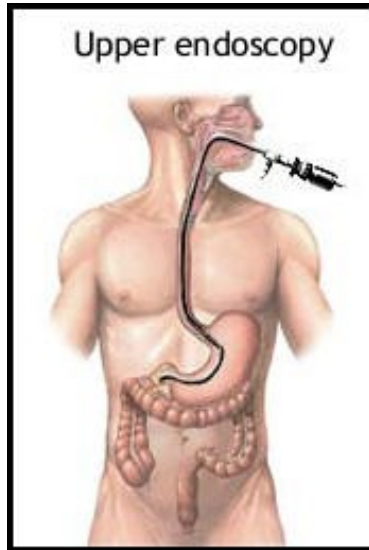
- **Mouth:** The oval-shaped oral cavity located at the apex of the digestive tract and consisting of two parts: the vestibule and the oral cavity proper.
- **Pharynx:** A funnel-shaped fibromuscular tube that conducts food to the esophagus, and air to the larynx and lungs. It is divided into the nasopharynx; oropharynx; and hypopharynx (laryngopharynx).
- **Upper Gastrointestinal Tract:** The segment of gastrointestinal tract that includes the esophagus, stomach and the duodenum.

(Source: MeSH Database)

Procedures

Currently, the most commonly used imaging methods for detection of gastrointestinal disorders, including disorders of the small intestine, are endoscopy and radiological imaging.

A traditional endoscope is a device consisting of a flexible tube and an optical system. There are several types of endoscopic procedures used to identify disorders in the gastrointestinal tract. The basic endoscopic procedures available include:

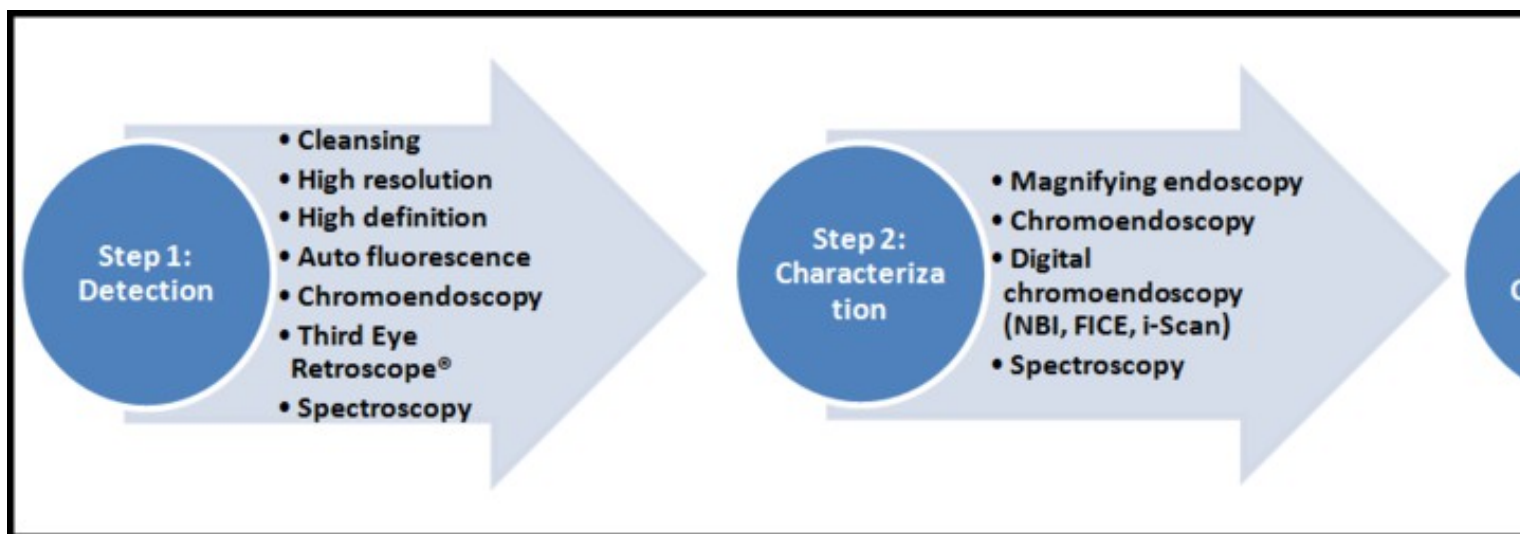


Upper Endoscopy

- **Upper Endoscopy:** In upper endoscopy, the physician inserts an endoscope, which is an approximately 3.5 foot long tube, through the patient's mouth. In esophagogastroduodenoscopy, or EGD, the gastroscope passes down the esophagus and into the stomach and duodenum for visual examination. In esophagoscopy, only the esophagus is viewed.
- **Colonoscopy:** In colonoscopy, the physician inserts a colonoscope, which is an approximately 5.5 foot long endoscope, into the patient's colon through the anus. Colonoscopy is the primary method for detecting disorders of the colon and is the standard screening tool for early detection of colon cancer.
- **Push Enteroscopy:** Push enteroscopy involves the insertion of an approximately six-foot long push enteroscope into the mouth. Due to the length and curvature of the small intestine, push enteroscopy enables the physician to view only the first one-third of the small intestine. The procedure is time consuming and difficult to perform for the physician and significantly more difficult to bear for the patient compared to traditional endoscopy.
- **Double Balloon Endoscopy:** The technique involves the use of a balloon at the end of a special enteroscope camera and an overtube, which is a tube that fits over the endoscope, and which is also fitted with a balloon. The procedure is usually done under general anesthesia, but may be done with the use of conscious sedation.

GI Imaging

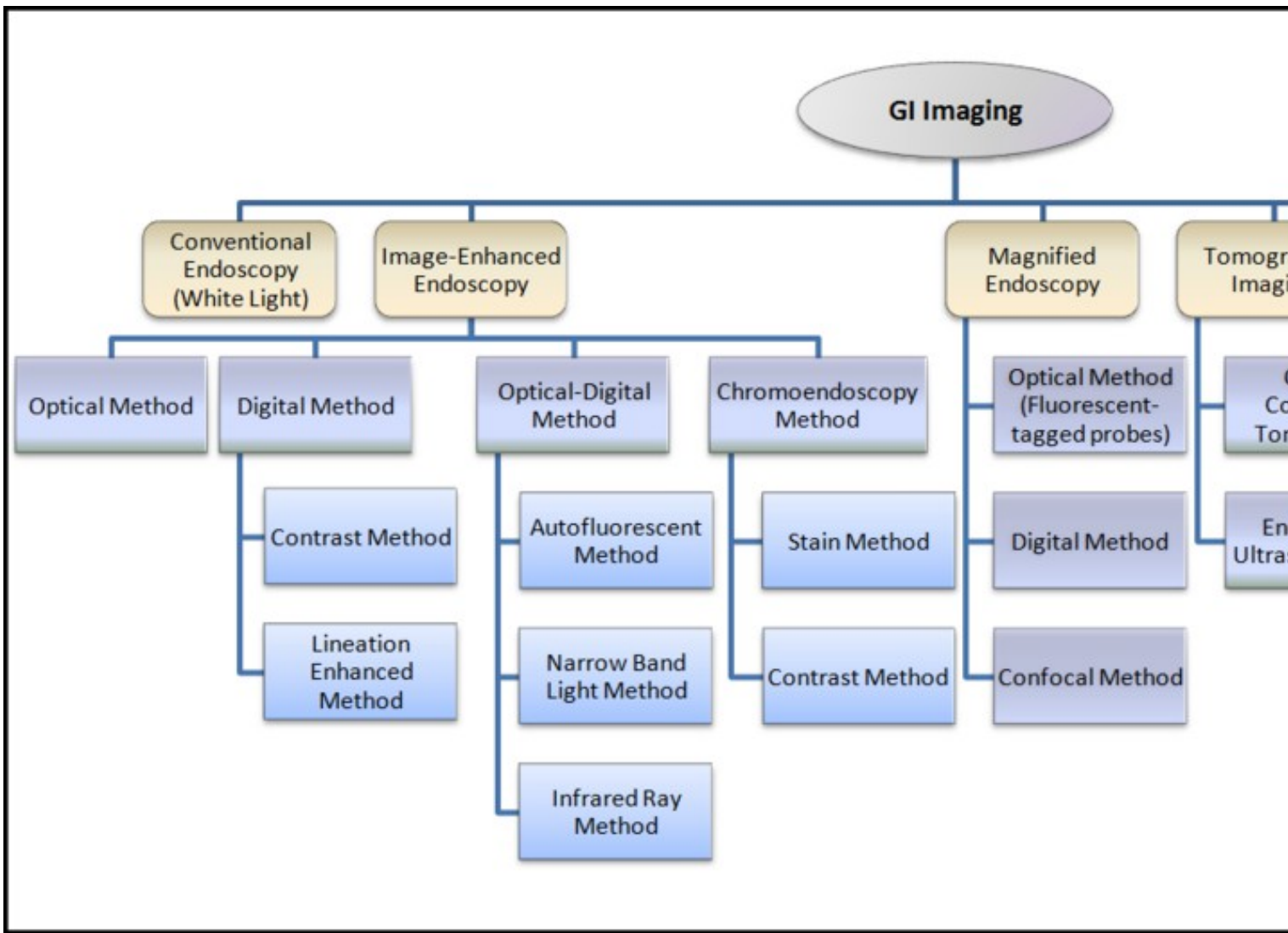
Gastrointestinal endoscopy is undergoing major improvements, which are driven by new available technologies and substantial refinements of optical features. Detection, characterization and confirmation are essential steps required for proper endoscopic diagnosis. Optical and nonoptical methods can help to improve each step; these improvements are likely to increase the detection rate of neoplasias and reduce unnecessary endoscopic treatments. Furthermore, functional and molecular imaging are emerging as new diagnostic tools that could provide an opportunity for personalized medicine, in which endoscopy will define disease outcome or predict the response to targeted therapy.



Key steps to endoscopic diagnosis

Several new technologies are now available for each step, some of them include:

- **Narrow-Band Imaging(NBI)** by Olympus America, uses filter to illuminate mucosa at specific wavelength
- **Fujinon Intelligent Color Enhancement(FICE)** by Fujinon, uses Spectral endoscopic image processing technology which has been developed to estimate spectral information from RGB image data obtained through a routine endoscopy and to better characterize mucosal tissue structures
- **I-Scan** by Pentax Medical, a next generation technology, is a dynamic, multimodal tool revealing the hidden colors, topography, vascularity, and structure of disease. i-SCAN explores the possibility of the first electronic version of chromoendoscopy (e-Chrome?) through the use of complimentary color filters and enhancements
- **Third Eye Retroscope®** by Avantis Medical Systems, an additional small-caliber endoscope that can be passed over the working channel of standard colonoscopes with the possibility of retro view?leads to a substantially increased detection of neoplastic changes
- **Endoflag** by Endopix, is a single filter, single-pass implementation that processes standard or high-definition video sequences after acquisition



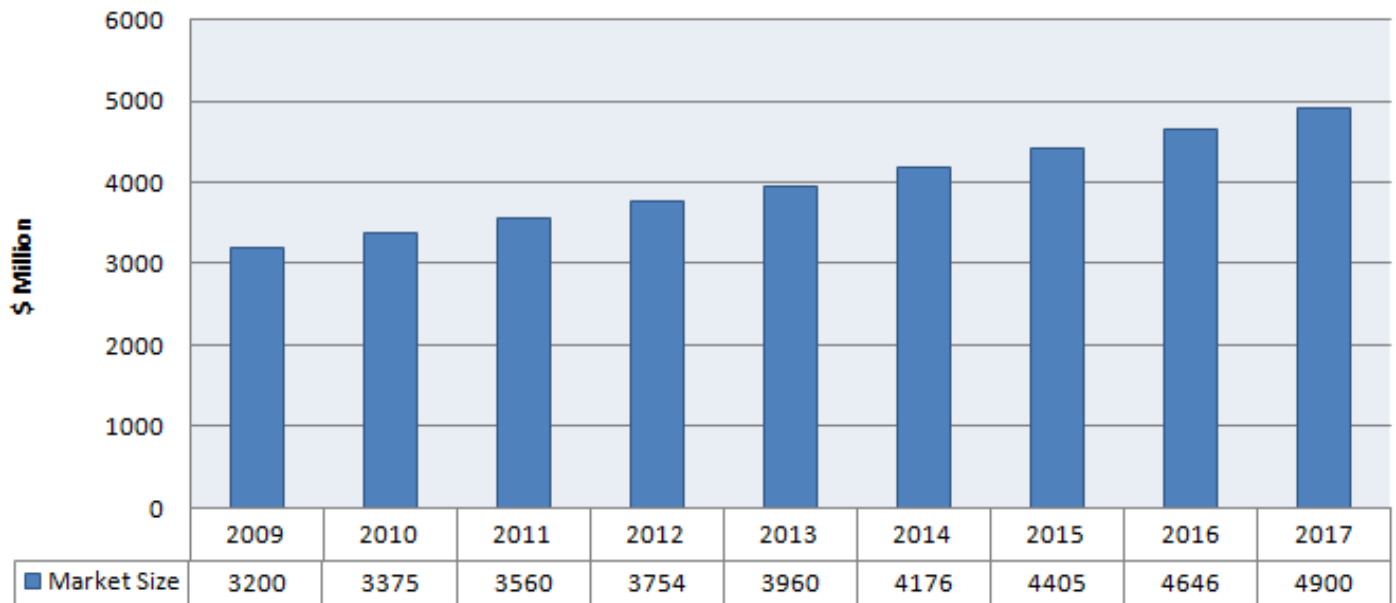
Classification of GI Imaging

Product Portfolio Heat Map

This is supposed to be a flash animation. You'll need the flash plugin and a browser that supports it to view it.

Market Size

GI Endoscopy Market Size



Source: Business Insights, Global Industry Analysts, Inc.

Major Players

Detailed Company Profile

Olympus Corporation

Snapshot Profiles

- Boston Scientific
- Conmed
- Covidien
- Ethicon Endo
- Fujinon
- Given Imaging
- Karl Storz
- Hoya Corporation
- Stryker

Source: Kalorama, Company website, Company SEC filings

M&A Activity

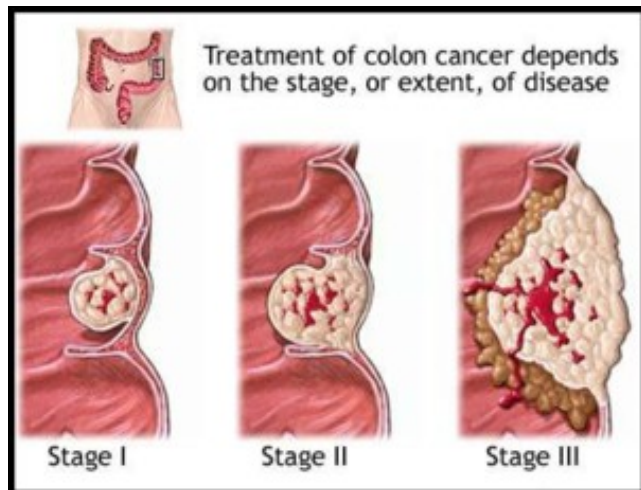
S.No.	Date	Details
1	Oct-10	Cook Medical Receives Two Contract Awards with HealthTrust Purchasing Group for Enteral Feeding and GI Endoscopic Supplies
2	Apr-10	Given Imaging Ltd acquires Sierra Scientific Instruments from Water St Healthcare Partners
3	Apr-10	Fujifilm signs a comprehensive Joint R&D agreement with Fox Chase cancer center
4	Mar-09	KARL STORZ Acquires Global Care Quest
5	Jan-09	Given Imaging Inks Distribution Agreement with FUJIFILM
6	Dec-08	Given Imaging Ltd. Acquires Medtronic Bravo(R) pH Monitoring Business
7	Nov-08	Smiths Group Acquires Zhejiang Zheda Medical Instrument
8	Nov-08	Visage Imaging Inks Marketing Agreement with Viatronix
9	Jul-08	FUJIFILM Merges Fujinon's Endoscope Business into Medical System Business Division
10	Jun-08	ICAD and ACR Image Form Partnership to Initiate Colon-CAD Clinical Study
11	Mar-08	Karl Storz Inks Deal with EndoGastric for Marketing EsophyX and StomaphyX
12	Mar-08	Given Imaging Bags a 5-Year FSS Contract
13	Nov-07	Olympus Takes Over Gyrus Group

14	Aug-07	PENTAX and HOYA Merge
15	Apr-07	Boston Scientific to acquire Remon Medical Technologies

Procedure Volumes

The three main areas where GI Endoscopy has considerable applications are Colon/Rectum cancer, Obesity (gastric bypass/gastric banding) and Digestive system disorders.

Colon/Rectum cancer



Stages of Cancer

Tumors or cancer of the colon or the rectum or both. Colorectal cancer starts in the large intestine (colon) or the rectum (end of the colon). Risk factors for colorectal cancer include chronic ulcerative colitis; familial polyposis coli; exposure to asbestos; and irradiation of the cervix uteri. (MeSH) Colorectal cancer is the third most commonly diagnosed cancer in the world, but it is more common in developed countries.

Stages of colon cancer are:

- *Stage 0*: Very early cancer on the innermost layer of the intestine
- *Stage I*: Cancer is in the inner layers of the colon
- *Stage II*: Cancer has spread through the muscle wall of the colon
- *Stage III*: Cancer has spread to the lymph nodes
- *Stage IV*: Cancer has spread to other organs

(For more information on colon cancer [click here](#))

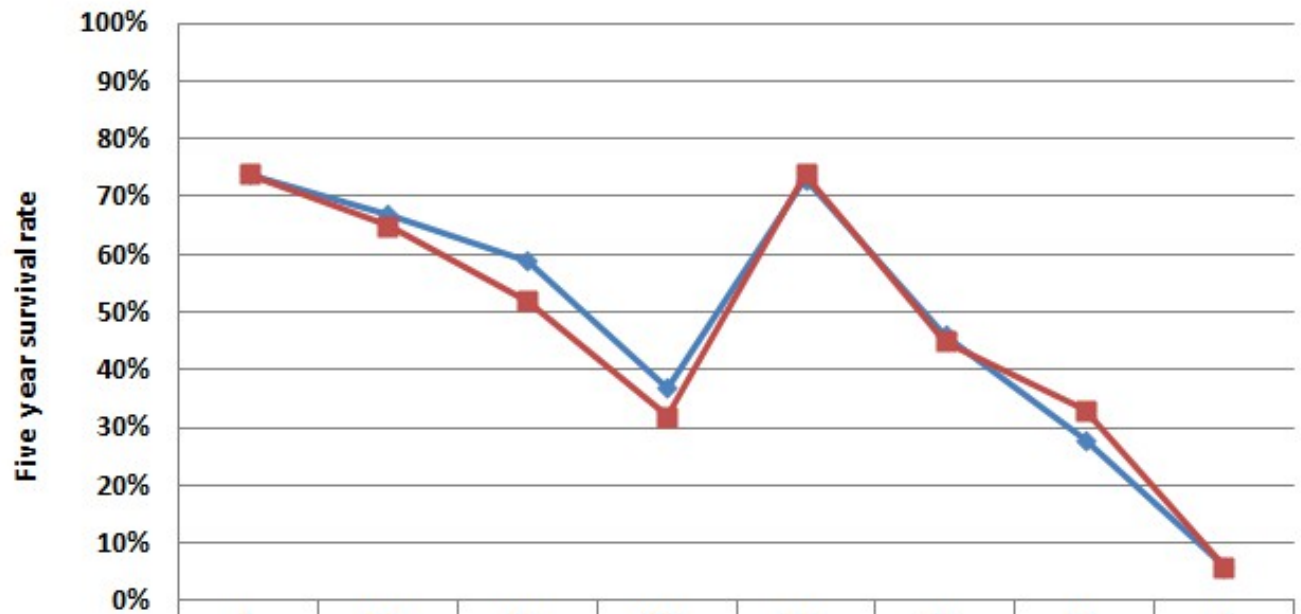
Volumes, Prevalence and Incidence

- Overall, the **lifetime risk** of developing colorectal cancer is about **1 in 20** (5.1%). This risk is slightly lower in women than in men.
- Cases estimated in the US in **2011** are:
 - ♦ **101,700** cases of colon cancer
 - ♦ **39,510** cases of rectal cancer
- Overall, colorectal cancer is the second-leading cause of cancer death in Canada.
 - ♦ In **2011**, an estimated **22,200** Canadians (12,500 men - 9,700 women) will be diagnosed with colorectal cancer and **8,900** (5,000 men - 3,900 women) will die from it.
 - ♦ **One in 14 men** is expected to develop colorectal cancer during his lifetime and **one in 27** will die from it.
 - ♦ **One in 15 women** is expected to develop colorectal cancer during her lifetime and **one in 31** will die from it.
 - ♦ On average, **426** Canadians will be diagnosed with colorectal cancer every week and **171** will die from the disease every week.

(Source: [Colorectal cancer association of Canada](#) & [American cancer society](#))

Survival Rates

Survival Rates for different Stages of Cancer



	1	2A	2B	2C	3A	3B	3C	4
Colon cancer	74%	67%	59%	37%	73%	46%	28%	6%
Rectal cancer	74%	65%	52%	32%	74%	45%	33%	6%



Source:SEERdatabase
Incidence rates

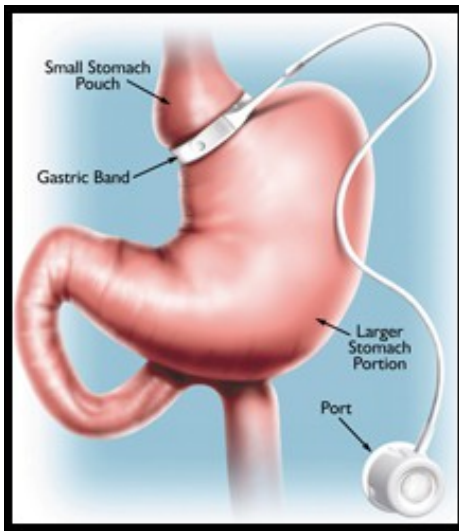
The estimated incidence rate of colorectal cancer in 2007 is expressed geography wise below:

Area	Incidence per 100,000 people
North America	17-33.5
Europe	17-33.6
Asia	17-33.7
South America	17-33.4
Africa	3.2-17

Source: Kalorama Information Report

Obesity (Gastric bypass/Gastric banding)

A status with **body weight** that is grossly above the acceptable or desirable weight, usually due to accumulation of excess fats in the body. The standards may vary with age, sex, genetic or cultural background. In the Body mass index, a **BMI greater than 30.0 kg/m2** is considered obese, and a BMI greater than 40.0 kg/m2 is considered morbidly obese (morbid obesity).



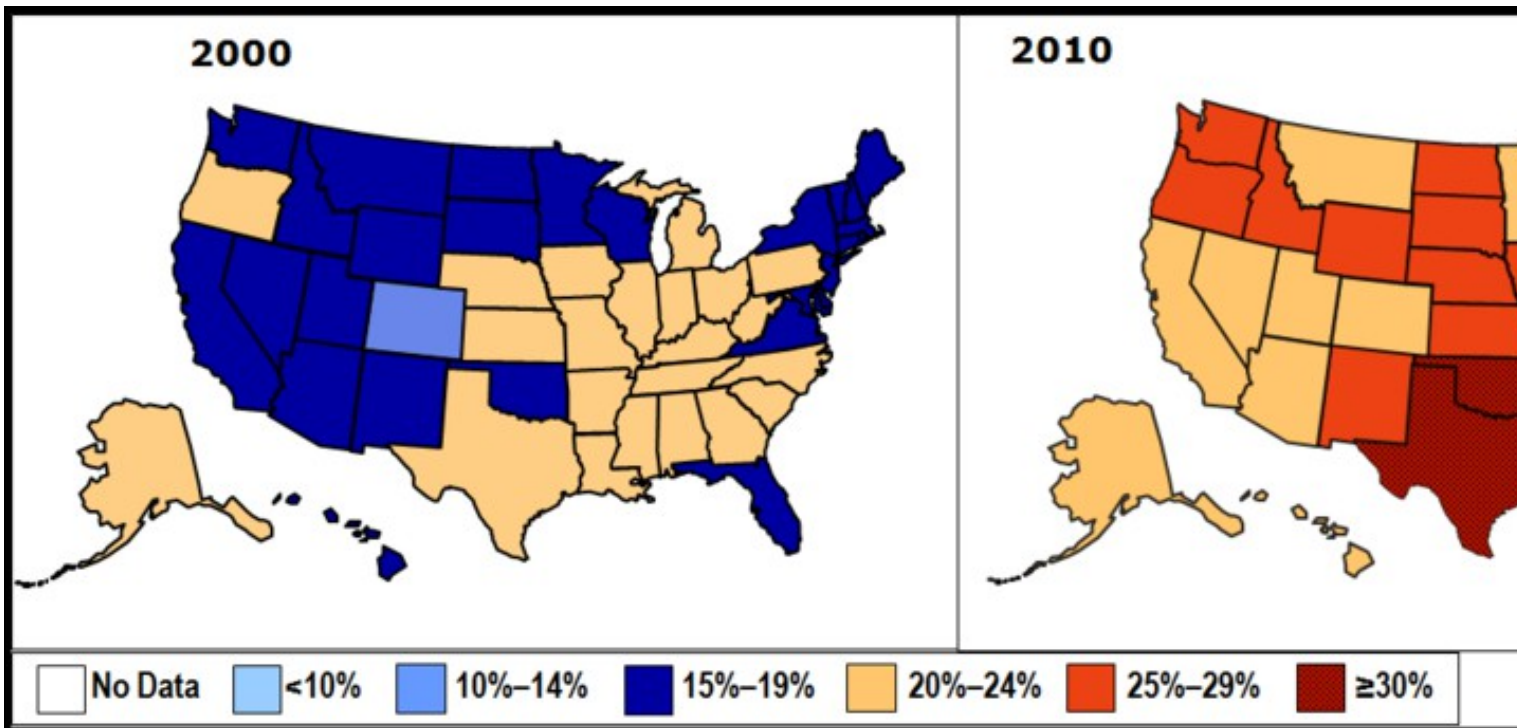
Laparoscopic Gastric Banding

The two most common weight-loss surgeries are:

- **Laparoscopic Gastric Banding** (also referred as lap band): The surgeon places a band around the upper part of your stomach, creating a small pouch to hold food. The band helps you limit how much food you eat by making you feel full after eating small amounts.
- **Gastric Bypass**: This surgery helps you lose weight by changing how your stomach and small intestine handle the food you eat. After the surgery, you will not be able to eat as much as before, and your body will not absorb all the calories and other nutrients from the food you eat.

Volumes, Prevalence and Incidence

- In **United States** obesity is estimated to cause an excess **111,909 to 365,000 deaths per year**
- **One million** (7.7%) of deaths in the **European Union** are attributed to excess weight.
- On an average, obesity reduces life expectancy by **six to seven years**:
 - ♦ A BMI of 30-35 reduces life expectancy by two to four years
 - ♦ While morbid obesity (BMI > 40) reduces life expectancy by 10 years
- Large-scale American and European studies have found that mortality risk is lowest at a BMI of 20-25 kg/m², with risk increasing along with changes in either direction. (Source: [thelancet](#) & [jama-ama-assn](#))
- **Obesity prevalence rate in USA**



Percent of Obese (BMI > 30) in U.S. Adults

Digestive system disorders

Diseases in any part of the gastrointestinal tract or the accessory organs (liver; biliary tract; pancreas). The digestive system disorders are categorized as:

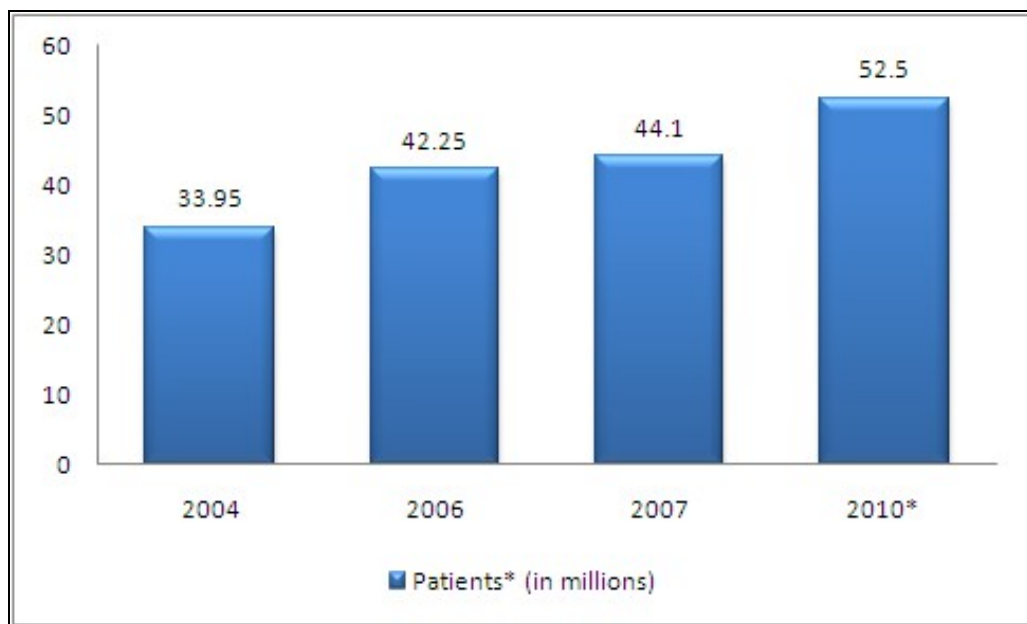
- Biliary Tract Diseases
- Digestive System Abnormalities
- Digestive System Fistula

- Digestive System Neoplasms
- Gastrointestinal Diseases
- Liver Diseases
- Pancreatic Diseases
- Peritoneal Diseases

(Source: MeSH)

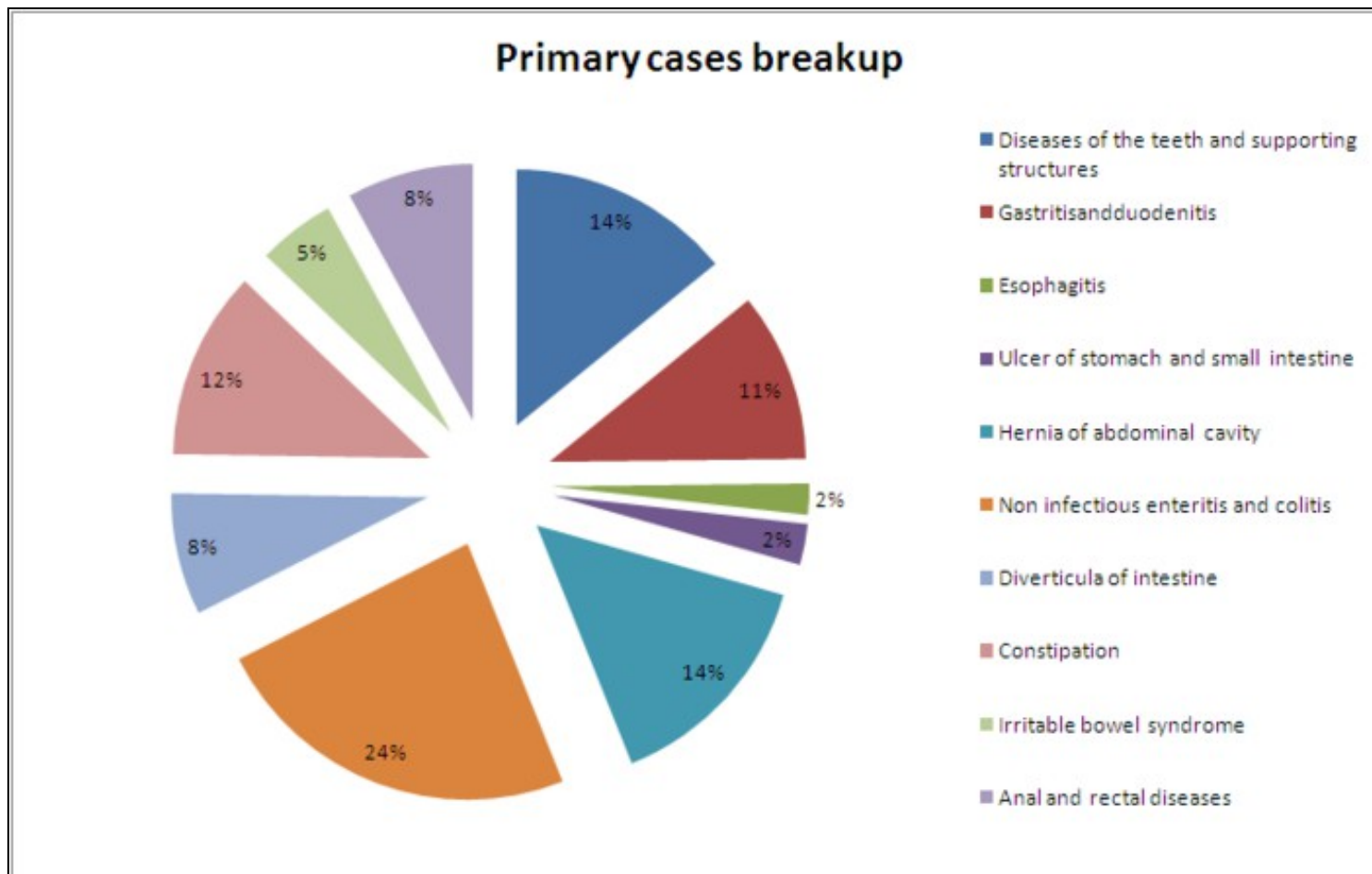
Volumes, Prevalence and Incidence

- Hospital visits in USA (Digestive disorders as the primary reason)



Source: CDC health statistics report

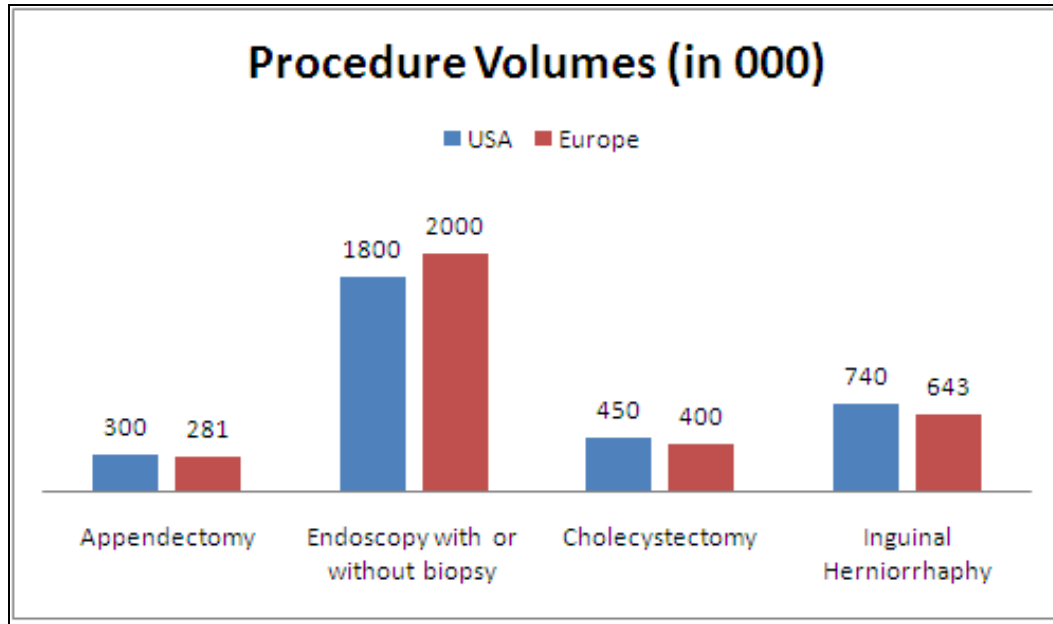
- Disease wise breakup (Digestive disorders as the primary reason)





Source: CDCsurvey

• USA and Europe Procedure Volumes



Source: Kalorama Information; WHO; US Census Bureau; Centers for Disease Control and Prevention

NOTE: All values for USA and Europe are in 000's. Data includes both in-patient and out-patient surgical procedures in all populations

Reimbursements

Upper GI/ Colonoscopy

CPT Code	Procedure	2008 National Average Medicare Payment Facility
43250	Upper GI endoscopy including esophagus, stomach and either duodenum and/or jejunum as appropriate; with removal of tumors, polyps, or other lesions by hot biopsy forceps or bipolar cautery	\$172.91
43251	Upper GI endoscopy including esophagus, stomach and either duodenum and/or jejunum as appropriate; with removal of tumors, polyps, or other lesions by snare technique	\$199.58
43255	Upper GI endoscopy including esophagus, stomach and either the duodenum and/or jejunum as appropriate; diagnostic, with control of bleeding any method	\$258.99
43256	Upper GI endoscopy including esophagus, stomach and either the duodenum and/or jejunum as appropriate; with transendoscopic stent placement (includes predilation)	\$233.09
43258	Upper GI endoscopy including esophagus, stomach and either the duodenum and/or jejunum as appropriate; with ablation of tumors, polyps, or other lesions not amendable by hot biopsy forceps, bipolar cautery or snare technique	\$244.14
45383	Colonoscopy, flexible, proximal to splenic flexure; with ablation of tumor(s), polyp(s), or other lesions(s) not amenable to removal by hot biopsy forceps, bipolar cautery or snare technique	\$307.36
45384	Colonoscopy, flexible, proximal to splenic flexure; with removal of tumor(s), polyp(s), or other lesion(s) by hot biopsy forceps or bipolar cautery	\$248.33
45385	Colonoscopy, flexible, proximal to splenic flexure; with removal of tumor(s), polyp(s), or other lesion(s) by snare technique	\$281.84
91110	Gastrointestinal tract imaging, intraluminal (e.g., capsule endoscopy), esophagus through ileum, with physician interpretation and report (Visualization of the colon is not reported separately)	\$944.18

Bariatric Surgery

APC	APC Description (Hospital Outpatient Dept)	Medicare Payment
130	Level I Laparoscopy (CPT 43659)	\$2,190.81

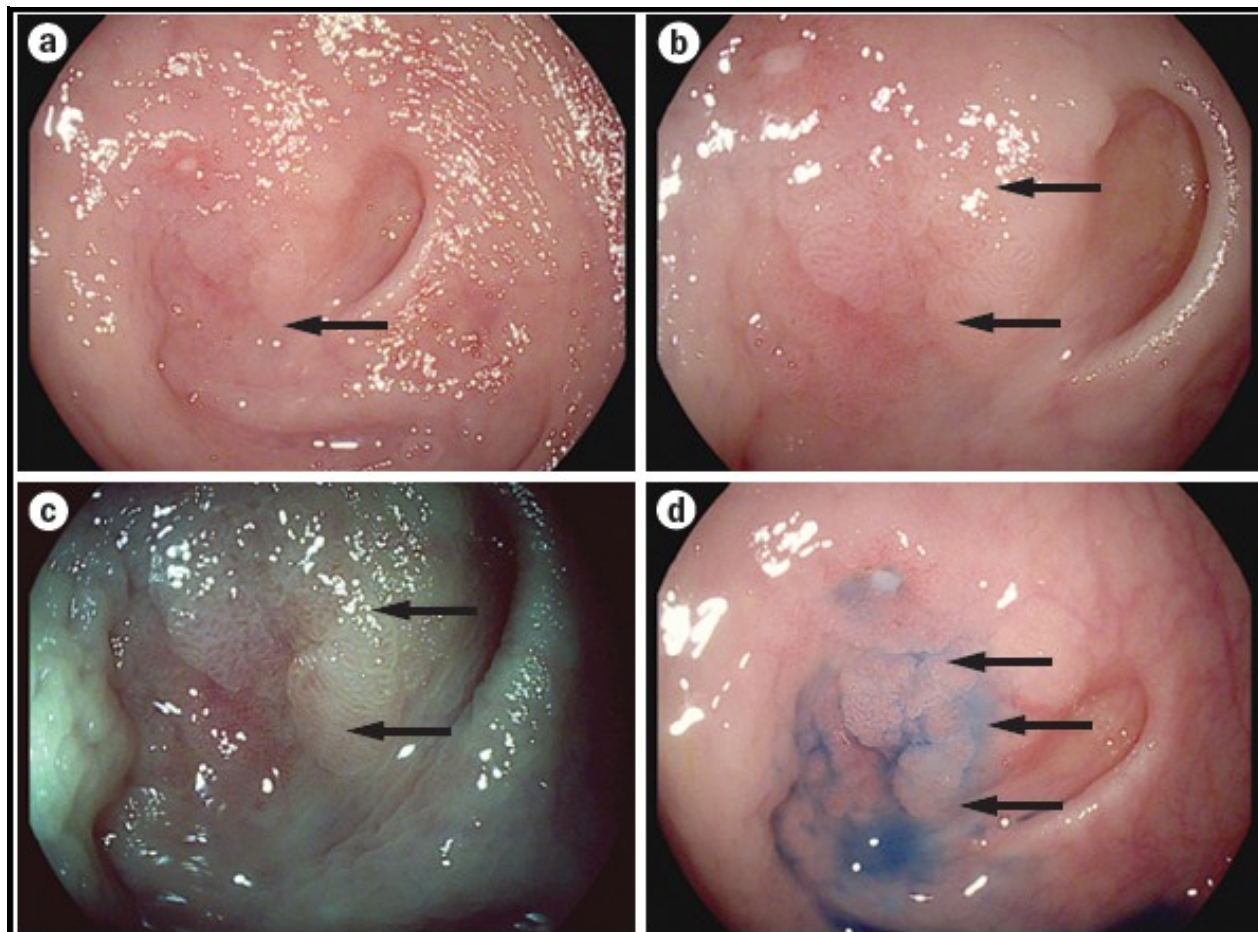
135	Level III Skin Repair (CPT 43887)	\$288.30
137	Level V Skin Repair (CPT 43886, 43888)	\$1,287.06
141	Level I Upper GI Procedure (CPT 43999)	\$541.59

CPT Code	Procedure	2008 National Average Medicare Payment Facility
43886	Gastric reconstructive procedure, open; revision of subcutaneous port component only	\$836.59
43888	Removal and replacement of subcutaneous port component only	\$836.59
43644	Laparoscopy, surgical, gastric restrictive procedure; with gastric bypass and Roux-en-Y gastroenterostomy (Roux limb 150 cm or less)	\$1,507.10
43645	Laparoscopy, surgical, gastric restrictive procedure; with gastric bypass and small intestine reconstruction to limit absorption	\$1,615.27
43659	Unlisted laparoscopy procedure, stomach (Removal and replacement of both adjustable gastric band and subcutaneous port component)	Carrier Priced
43770	Laparoscopy, surgical, gastric restrictive procedure; placement of adjustable gastric band (gastric band and subcutaneous port components)(use modifier - 52 for individual component placement)	\$970.08
43771	Laparoscopy, surgical, gastric restrictive procedure; Revision of adjustable gastric band component only	\$1,107.95
43772	Laparoscopy, surgical, gastric restrictive procedure; Removal of adjustable gastric band component only	\$833.72
43773	Laparoscopy, surgical, gastric restrictive procedure; Removal and placement of adjustable gastric band component only	\$1,107.95
43774	Laparoscopy, surgical, gastric restrictive procedure: Removal of adjustable gastric band and subcutaneous port components	\$838.29
43842	Gastric restrictive procedure, without gastric bypass, for morbid obesity; vertical banded gastroplasty	\$1,071.01
43843	Gastric restrictive procedure, without gastric bypass, for morbid obesity; other than vertical banded gastroplasty	\$1,097.67
43845	Gastric restrictive procedure with partial gastrectomy, pylorus-preserving duodenoileostomy (50 to 100 cm common channel) to limit absorption (bilopancreatic diversion with duodenal switch)	\$1,716.20
43846	Gastric restrictive procedure, with gastric bypass, for morbid obesity; with short limb (150 cm or less) Roux-en-Y gastroenterostomy	\$1,416.07
43847	Gastric restrictive procedure, with small intestine reconstruction to limit absorption	\$1,553.19
43848	Revision of gastric restrictive procedure for morbid obesity (separate procedure), other than adjustable gastric band	\$1,680.40
43886	Gastric reconstructive procedure, open; revision of subcutaneous port component only	\$287.18
43887	Removal of subcutaneous port component only	\$272.32
43888	Removal and replacement of subcutaneous port component only	\$387.34
43999	Unlisted procedure, stomach	Carrier Priced
S2083	Adjustment of gastric band diameter via subcutaneous port by injection or aspiration of saline	Carrier Priced

Technology Advancements

Areas	Companies Involved
Enhanced Imaging Modalities	Olympus Medical System Corp.
	Pentax Crop. (Hoya Corporation)
	Fujinon
	Mauna Kea Technologies

	KARL STORZ
	SpectraScience Inc.
Robotic-Assisted Endomicroscope	EndoControl Inc.
Wireless Biosensors and Polymers for GI bleeding (Hemostasis)	Pluromed Inc.
Electronic Nose "Smells" Disease	Cyrano Science Inc.



Enhanced Imaging Modalities: High-definition and virtual chromoendoscopy; (a) White-light imaging during endoscopy; a lesion beside a diverticular is hardly visible (arrow). (b) Closer inspection and image enhancement reveals tubular surface structures (arrows); (c) Virtual chromoendoscopy leads to pseudocolorization and improved visualization of the flat adenoma (arrows); (d) Chromoendoscopy using methylene blue unmask the full extent of the lesion (arrows).